

Dr. med. Dr. med. dent. Martin Keweloh

Mutlangen/Germany



RATIOPLANT®-IMPLANTS
CASE STUDY



Curriculum vitae

Dr. med. Dr. med. dent. Martin Keweloh

University:

06/1993 Registration as a dental surgeon
(University of Ulm/Baden-Wuerttemberg/Germany)
08/1999 Registration as a medical doctor
(University of Erlangen-Nuernberg/Bavaria/Germany)



Address:

Wetzgauer Str. 73
D-73557 Mutlangen/Germany
Fon: +49 7171 999774
mobile: +49 178 2992392
E-Mail: sg-implant@praxisklinik-mkg.de
Web: www.praxisklinik-mkg.de

Certified specialist for Implantology and Periodontology
(DGMKG, DGI, DGZI, BDO, BDIZ)

Member of the board of the German Association for Maxillo-Facial Surgery (Section Implantology)

Editor of the german journal "Implantologie-Zeitung"

Member of DGMKG (German Association for Maxillo-Facial Surgery-SPEAKER), DGI (German

Association for Implantology (Speaker), GAECD (Association for Aesthetic-Plastic Surgery Germany),
DGPW (German Association of Plastic and Reconstructive Surgery)

Speaker on national and international conferences:

(EACMFS: Edinburgh/Scotland 2000, PAAOMS: Dubai/VAE 2001, Int. Camlog-Congress: Montreux/
Switzerland 2006, EACMFS: Bologna/Italy 2008, ANZAOMS Christchurch/New Zealand 10/2008,
Melbourne 7/2009, ANZAOMS Goldcoast/Austr. 10/09)

RATIOPLANT®-IMPLANTS

CASE STUDY

Patient Data

The patient is a 47-year-old, healthy male.
The bone in the area of 46 would be considered Type 2 bone (Figures 1, 2, 3 and 4).

Diagnosis

Edentulous, 46 area after cutting a bridge (45-47) and temporary crown on 45

Treatment Plan

The optimal treatment plan was determined to be an implant retained crown to replace 46

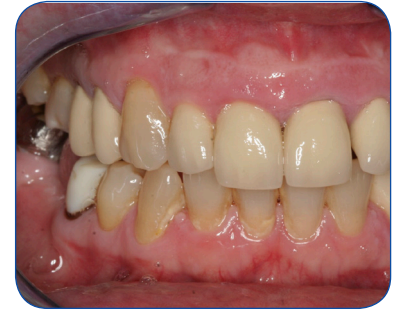

Figure 1

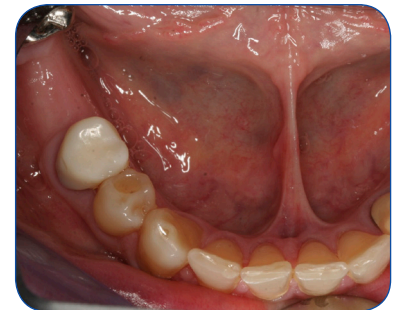

Figure 2

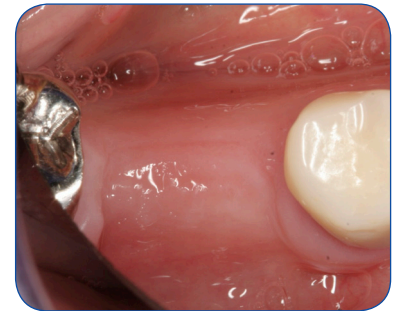


Figure 3

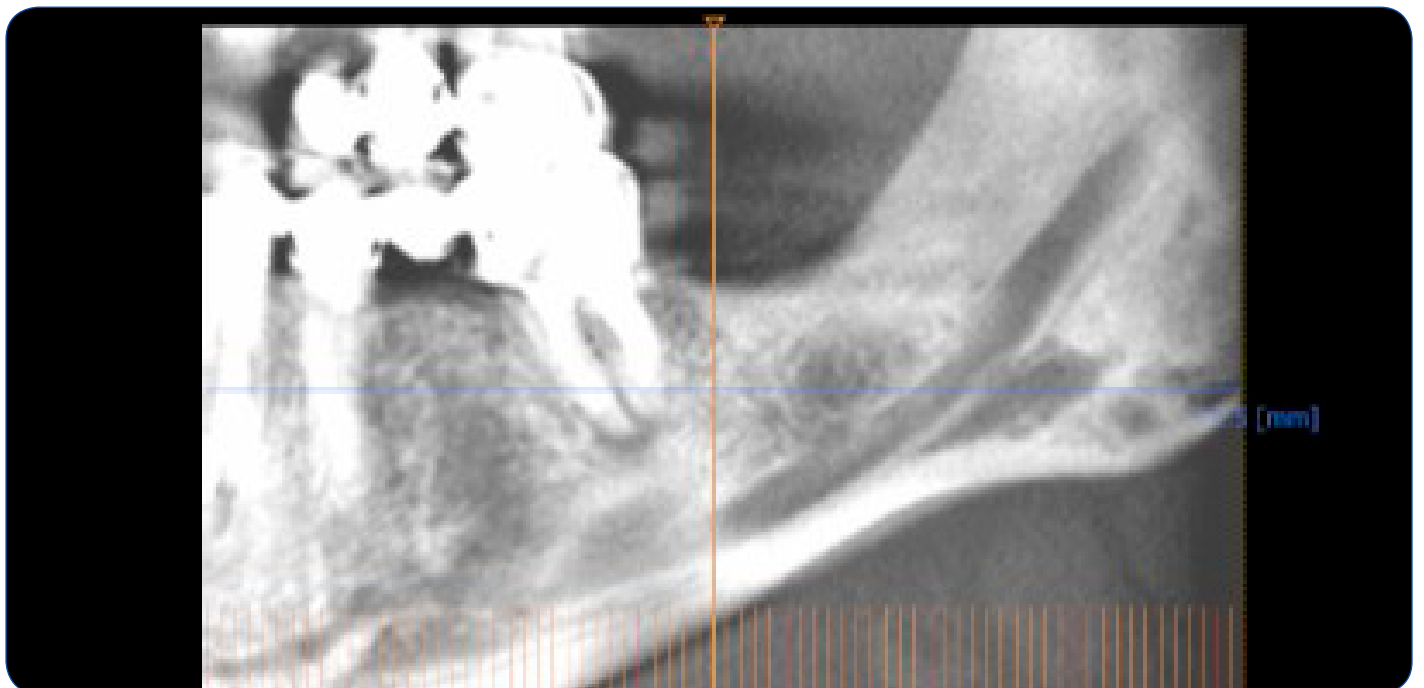

Figure 4

Procedure / Method

Implant planning by a computer-aided planning system (Figures 5 and 6).

Preparing of the mucosal flap (Figure 7).

Punch-marking to define the implant position (Figure 8).

Pilot-drilling (Figure 9).

Extension-drilling in steps up to final drill (Figure 10).

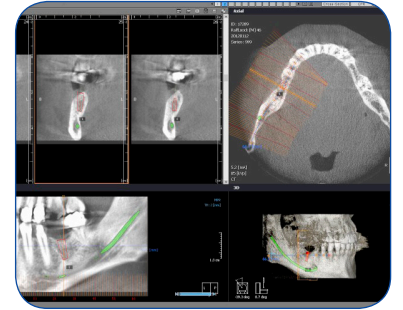


Figure 5

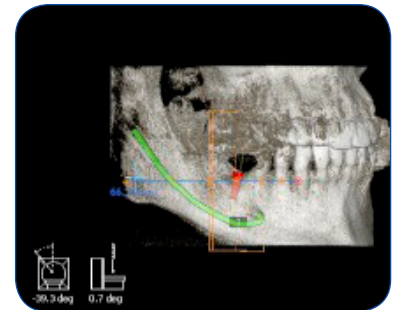


Figure 6

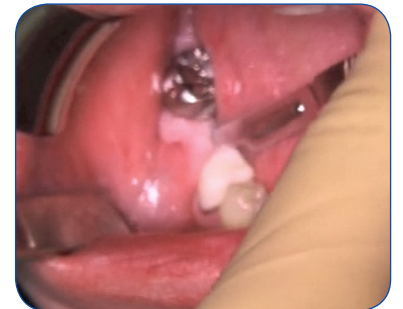

Figure 7

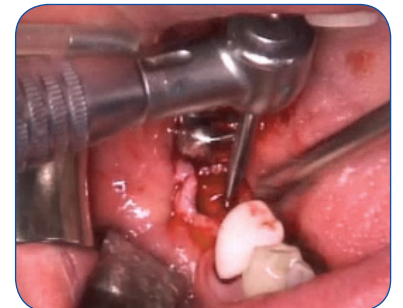

Figure 8

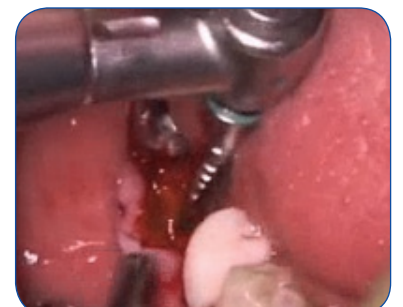

Figure 9

Procedure / Method - continued

Thread-cutting by hand using corresponding thread-cutter and a ratchet (Figure 10).

Setting of the RatioPlant Classic implant \varnothing 4.2 mm and length 10mm (Figure 11 and 12)

A corresponding cover screw was now placed and hand tightened (Figure 13).

A mucosal transplant was taken from soft palate and fixed inside to the mucoperiosteal flap and filled with bone graft before closing. The wound was closed using 3/0 plain gut suture. The patient was recalled one week later, and the soft tissue was well healed (Figure 14).

Control by radiography after closing (Figure 15).

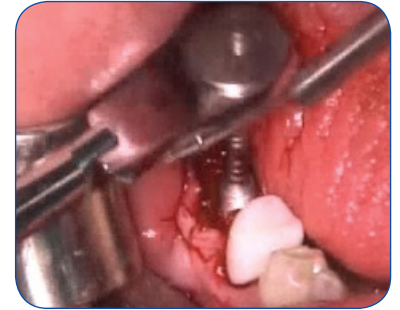


Figure 10

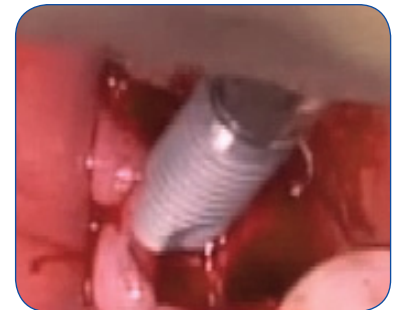

Figure 11

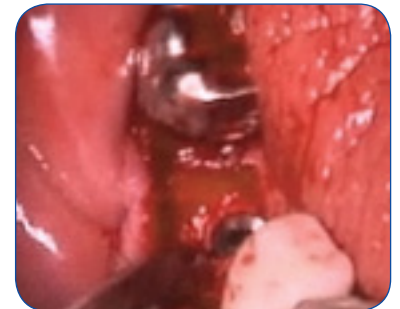

Figure 12

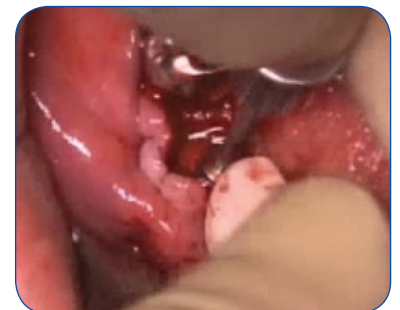

Figure 13

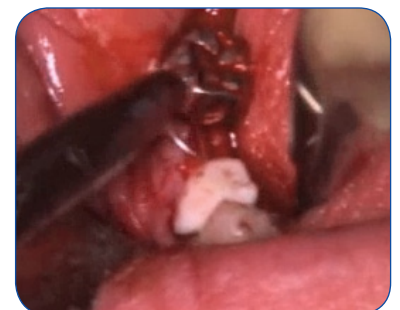

Figure 14

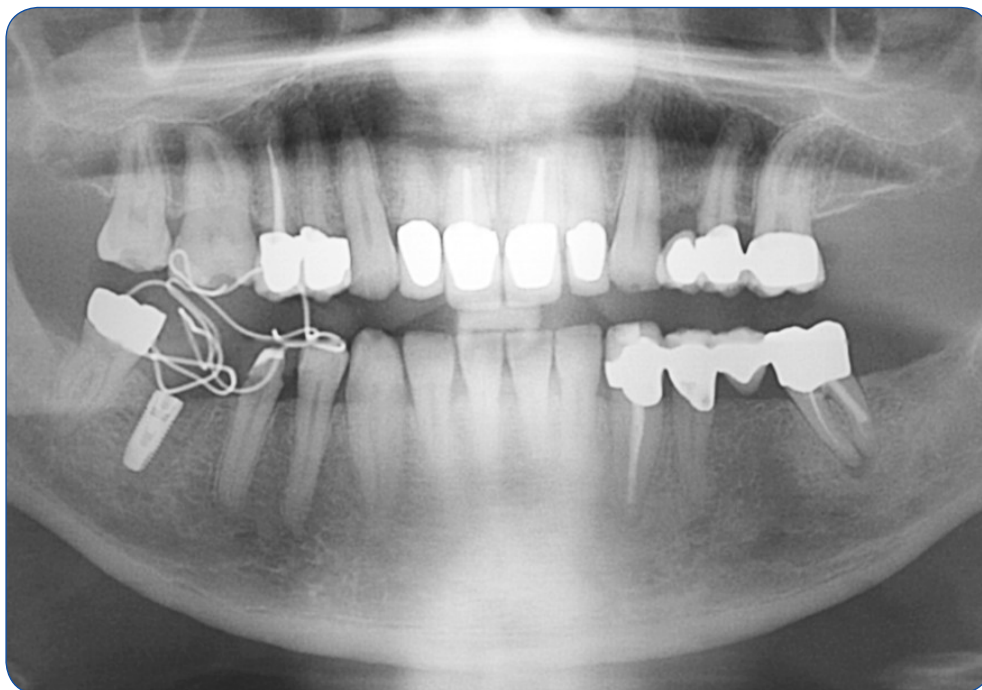


Figure 15

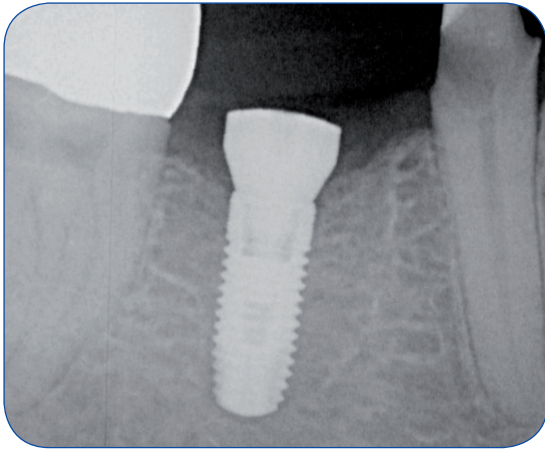


Figure 16

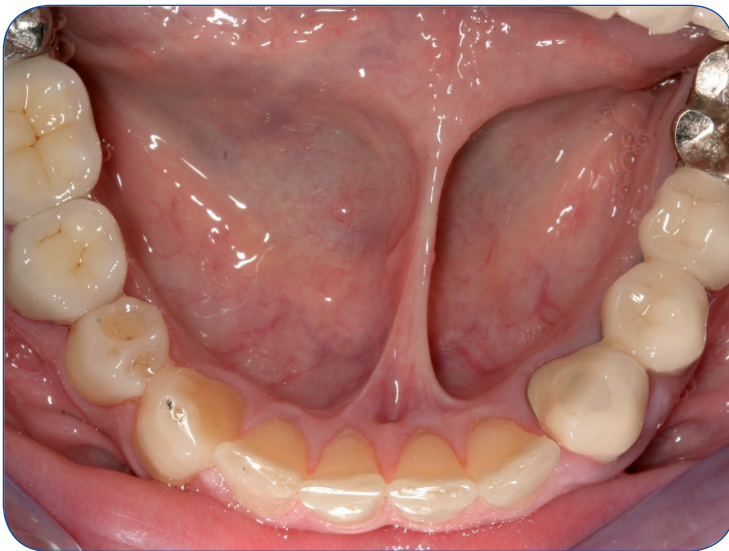

Figure 17

Follow-Up

The patient was recalled four months later, and the implant was checked clinically and radiographically (Figure 16). The implant was deemed integrated, and the prosthetic crown was then fabricated (Figure 17).

Results

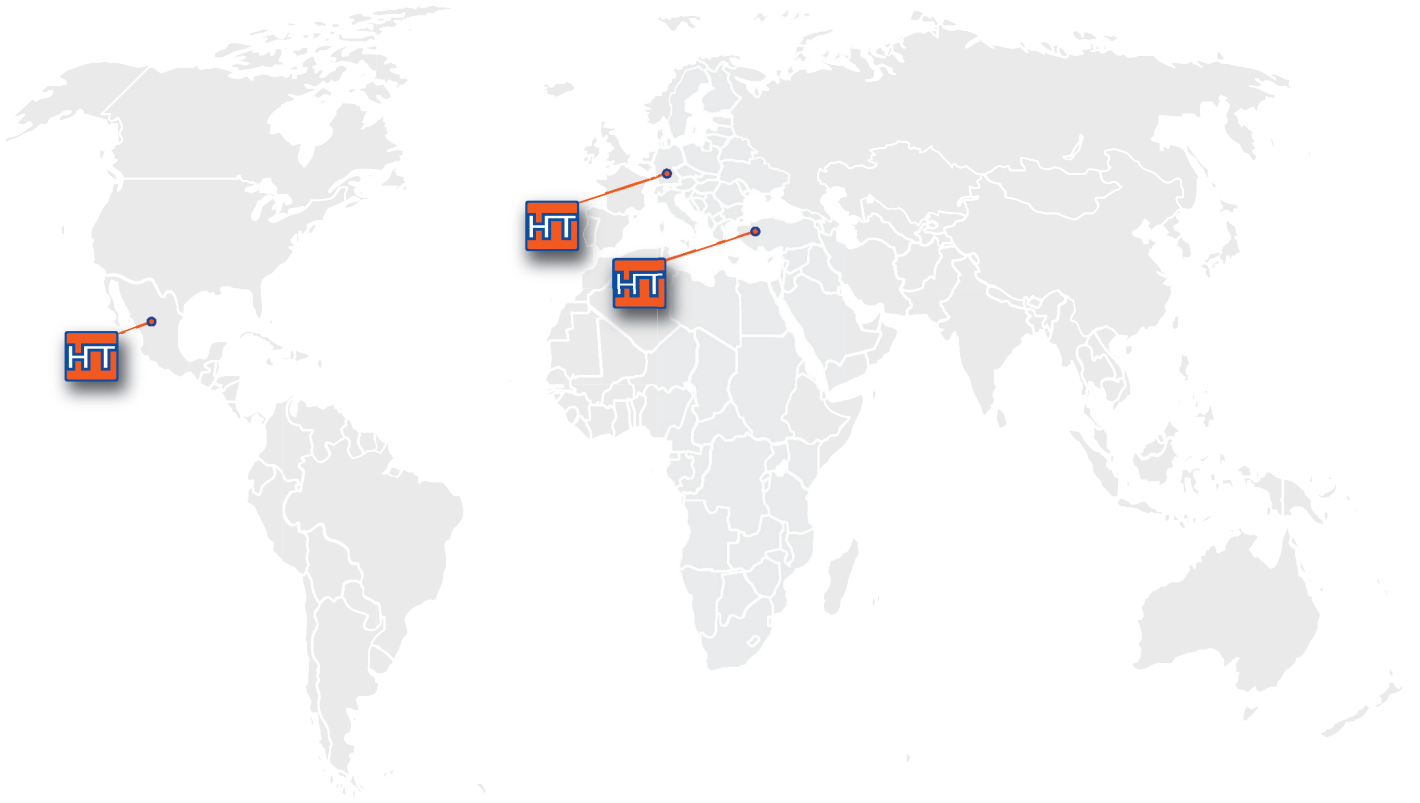
The implant has been under function for 12 months and has caused no bone loss or other complications.

The gingiva is pink and healthy, with no perio pocketing.

Conclusion

I feel the RatioPlant Implant System is a well-designed and easy to use implant delivery system, as all parts and instruments functioned extremely well. The implant has integrated well, and the tissue response has been excellent. I would expect this implant to function for many years without any complications.

Notes:



HumanTech Germany GmbH
Gewerbestr. 5
D-71144 Steinenbronn
Germany
Tel.: +49 (0) 7157/5246-71
Fax.: +49 (0) 7157/5246-33
info@humantech-solutions.de
www.humantech-solutions.de